



Emergence of tick-borne encephalitis (TBE) in the Netherlands

Margriet Dekker^a, Gozewijn Dirk Laverman^a, Ankje de Vries^b, Johan Reimerink^b, Felix Geeraedts^{c,*}

^a Department of Internal Medicine, Ziekenhuis Groep Twente, Almelo, Hengelo, the Netherlands

^b Center for Infectious Disease Control, National Institute for Public Health and the Environment (RIVM), Bilthoven, the Netherlands

^c Laboratory for Medical Microbiology and Public Health, Hengelo, the Netherlands

ARTICLE INFO

Keywords:

Flaviviridae
Emerging diseases
Tick-borne diseases
Tick-borne encephalitis - TBE
Viral infections
Zoonotic infections

ABSTRACT

Recently, tick-borne encephalitis virus (TBEV) was detected in the Netherlands for the first time, in ticks collected in 2015 in the National Park *Sallandse heuvelrug* in response to the detection of anti-TBEV antibodies in roe deer. Hereafter, two human cases of autochthonous TBE have been reported, occurring in 2016. One case was geographically linked to the area of the previously reported ticks, which harbored a genetically divergent TBEV-Eu strain variant (TBEV-NL). So far these are the few reported events that point to endemic transmission of TBEV in the Netherlands and the true prevalence of TBEV and TBE disease in the Netherlands and its impact on the human population remains to be determined. We describe the third human case, identified in 2017, which geographically clusters with the aforementioned case and TBEV-positive ticks. We also describe the identification of another TBEV-NL-positive tick in the Netherlands, collected 2 years after the initial find in that same region (in 2017). These observations support the concept of continued circulation of TBEV-NL and the presence of a possible TBEV hot spot in the *Sallandse Heuvelrug* region.

1. Introduction

Tick-borne encephalitis (TBE) is a neurologic disease caused by tick-borne encephalitis virus (TBEV), a single-stranded RNA virus of the family *Flaviviridae*. Three subtypes of TBEV are discerned; the European (TBEV-Eu), Siberian (TBEV-Sib), and Far Eastern (TBEV-FE) (Lindquist and Vapalahti, 2008). Recently, a new subtype diverging from TBEV-Sib has been proposed; Baikalian (TBEV-Bkl) (Kovalev and Mukhacheva, 2017). Also, another subtype, Himalayan (Him-TBEV), was recently identified in wild rodents (Dai et al., 2018). In Western Europe, TBEV-Eu is the prevailing subtype which is primarily transmitted by the tick *Ixodes ricinus*, and small rodents are its natural host. Transmission of TBEV to humans occurs within minutes after tick bite, producing disease in an estimated third of the cases. TBE-Eu has a typical bi-phasic course starting with a prodromal phase with flu-like symptoms, followed by a symptom-free interval before neurologic symptoms occur, varying from mild meningitis to severe encephalitis with or without myelitis and spinal paralysis (Lindquist and Vapalahti, 2008; Kaiser, 2012).

In the Netherlands TBE was considered an imported disease until May 2016, when in a survey in the National Park *Sallandse Heuvelrug* 2 out of 1460 *Ixodes ricinus* ticks collected in 2015, tested positive for

TBEV (National Institute for Public Health and the Environment (RIVM), 2016; Jahfari et al., 2017). Sequence analysis revealed a TBEV-Eu variant (TBEV-NL) which was genetically different from the common TBEV-Eu strain, showing 91% identity with TBEV-Eu Neudörfel strain (Jahfari et al., 2017). Shortly hereafter two human cases of endemic TBE were encountered in June 2016 (de Graaf et al., 2016; Weststrate et al., 2017). The first case contracted the tick-bite presumably on the *Utrechtse heuvelrug*, a region distant from the *Sallandse heuvelrug*. The identity of the TBEV strain was recovered from the biting tick but proved to be unrelated to TBEV-NL, and instead showed 99% identity with TBEV-Eu Neudörfel strain (de Graaf et al., 2016). The second case (Patient A, Weststrate et al., 2017) however, was geographically linked to the *Sallandse Heuvelrug* region where the TBEV-positive ticks had been found, but there was no direct evidence as to which specific TBEV strain was involved (Weststrate et al., 2017).

Much about the eco-epidemiology of TBEV and TBEV disease in the Netherlands and the risk it poses is still unknown. So far very few TBEV-positive ticks have been detected and only at one time-point. The two human cases seem unrelated and their presumed causative TBEV strains may point to circulation of different TBEV-Eu strains in different areas in the Netherlands. TBEV may have been present in the Netherlands for a longer time, as the sero-positivity of roe deer caught in 2010 may

* Corresponding author.

E-mail address: f.geeraedts@labmicta.nl (F. Geeraedts).

<https://doi.org/10.1016/j.ttbdis.2018.10.008>

Received 30 June 2018; Received in revised form 16 October 2018; Accepted 24 October 2018

Available online 25 October 2018

1877-959X/© 2018 Elsevier GmbH. All rights reserved.

suggest, and cases in the past may have been overlooked (Jahfari et al., 2017; Weststrate et al., 2017). Also, the limited number of human cases so far may represent an underestimation, due to unawareness by clinicians. Furthermore, there is still no direct proof that TBEV-NL infects and cause disease in humans.

2. Case

On 11 July 2017 (day 0), a 51 year-old woman (Patient B) presented with complaints of nausea, muscle ache and head ache. She had a one-day history of diarrhea after eating salmon two weeks before presentation, and fever in the past week. Physical examination showed no abnormalities; blood analysis showed increased liver enzymes and a leukocytopenia. She remembered two tick-bites without erythema migrans on June 22 and June 30; the latter firmly anchored in the skin between her toes. The differential diagnosis included bacterial gastroenteritis for which azithromycin was started on day 0, and Lyme borreliosis. In the following days blood abnormalities normalized, but complaints of nausea, stomach ache and diarrhea persisted. Serology for *Borrelia burgdorferi* sensu lato (IgM and IgG ELISA; VirionSerion, Germany) proved negative on day 2. In absence of neurological symptoms, but because patient B had been walking on the day of the 30 June tick-bite in a range within 1 km of the home address of patient A, i.e. the area where he possibly had contracted TBEV (Weststrate et al., 2017), TBE serology was performed. The geographic location of the 22 June tick bite is less clear. In a window of several weeks, she had been walking frequently on the *Sallandse heuvelrug* in the area between the home address of patient A and the location where TBEV-NL was initially discovered in ticks (Jahfari et al., 2017), but also in the neighborhood of her own house, which is relatively close to that of the second Dutch TBE case (Fig. 1). Serum taken on day 2 turned out weakly positive for anti-TBEV IgM (87 Vienna units (VIEU)/ml; cut-off: 63 VIEU/mL) and negative for anti-TBEV IgG. Serum taken on day 11 showed a seroconversion to IgG (529 VIEU/ml; cut-off: 100 VIEU/mL) and an increase in IgM titer (542 VIEU/ml), suggesting an acute infection with TBEV. This was confirmed by virus neutralization assay on serum of day 11 (VN; titer: 1:30). The patient had never been vaccinated against TBEV or any other flavivirus, and had not travelled abroad in the past three months. On day 8, she developed a constellation of neurologic symptoms (headache, dysarthria, photophobia, impaired concentration, and dizziness). This was diagnosed as encephalitis, and considered part of the natural course of TBEV infection with no further need for CSF

examination. Because there is no specific anti-viral therapy for TBE, treatment was supportive. On day 29, an MRI of the brain performed because of persistent dysarthria showed no abnormalities. Although her illness did not require hospitalization, she was not able to perform her normal daily activities for months and still was not fully recovered by March 2018.

3. Virus genome detection

For detection of TBEV genome in materials from the patient a real-time RT-PCR was used (Schwaiger and Cassinotti, 2003). This RT-PCR amplifies a 68-bp fragment of the 3' non-coding region of all 3 TBEV subtypes with a high sensitivity and specificity (Donoso Mantke et al., 2007). For nucleic acid extraction the automated MagNA Pure 96 system (Roche) was used. RT-PCR was performed on serum collected early in the infection (on day 2), and blood and urine collected shortly before the neurological symptoms (on day 9), as well as multiple (n = 11) urine samples collected during the neurological phase (on day 16–27). Because patient A in 2016 (Weststrate et al., 2017) also presented with diarrhea, stored purified RNA/DNA from the feces sample of patient B, that had been collected by the general practitioner on day 0, was also tested by RT-PCR. All samples turned out negative for TBEV RNA.

In parallel to the events described above, between April and July 2017, a number of nymphal and adult *Ixodes ricinus* ticks were collected within a 500 m radius of the home address of Patient A. After homogenizing the ticks using Lysis matrix Z (MPbiomedicals) and Fast prep FP120 homogenizer (Thermo Savant, Carlsbad, USA) RNA was extracted from 10 pools of 5 nymphs and 9 individual adult female ticks and 4 adult male ticks, and analyzed by RT-PCR as described above. One adult female tick out of in total 63 ticks collected and tested was found positive, and sequence analysis using primers and protocols as described elsewhere (Kupča et al., 2010), revealed a sequence that is 99.5% identical in the E-protein to the TBEV-NL strain found earlier in the National Park *Sallandse Heuvelrug* (Fig. 2; Jahfari et al., 2017).

4. Discussion

This is the third autochthonous case of a serologically proven TBEV infection in the Netherlands. A biphasic course reminiscent of TBE caused by TBEV-Eu may be discerned if the gastro-intestinal symptoms preceding the neurological phase are to be ascribed to side effects of azithromycin treatment, clouding an otherwise symptom-free interval. The mentioned episode with fever a week earlier may represent the prodromal phase of infection, more or less ending a few days after presentation.

TBEV is readily cleared from the blood and cerebrospinal fluid and is seldom detectable once neurologic symptoms appear (Holzmann, 2003). Unfortunately, we did not succeed in detecting viral RNA in patient materials, even though one of the blood samples was taken at the end of the prodromal phase (day 2), when viremia may still be present. Also, multiple urine samples collected during the neurological phase, when TBEV may still be detectable in urine (Veje et al., 2014), tested negative for viral RNA. There is, therefore, still no definitive proof that the TBEV-NL strain causes disease in humans. However, as was the case with patient A, this case strongly connects to the *Sallandse Heuvelrug* region, where TBEV-NL is the only strain encountered so far, albeit still in a low number of ticks (Jahfari et al., 2017). Therefore, it is tempting to assume that this strain is involved. However, the possibility that the ticks which transmitted the disease to patient A and B may have been transported by birds or other animals, and carried TBEV strains of a different origin cannot be excluded.

The exact location of the tick-bite of patient B is unknown but possible locations include the vicinity of the home of patient A, or the vicinity of her own home, both located within a close range of each other and also close to the locations where the TBEV-containing ticks

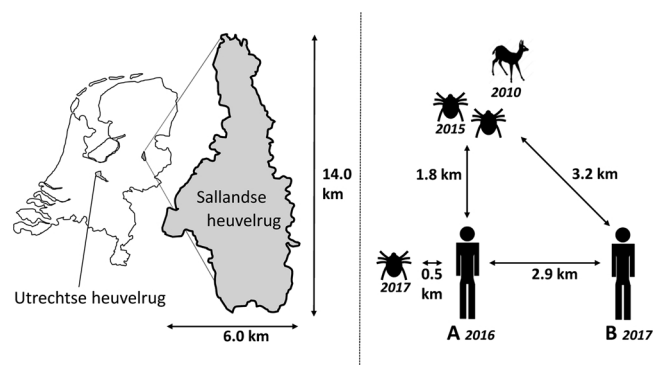


Fig. 1. Clustering of TBE cases and TBEV-positive ticks in and bordering the *Sallandse heuvelrug* region. Given are the estimated distances between TBEV-positive ticks and the homes of Dutch TBE cases (A and B), and the years in which the ticks were found TBEV-positive or when the TBE cases occurred (on the right). Preceding the identification of two TBEV-positive ticks in 2015, a serum sample of a roe deer in that location, collected in 2010, tested positive for anti-TBEV antibodies. On the left, the geographic location and size of the *Sallandse heuvelrug* region in the Netherlands is depicted. The first Dutch TBE case likely acquired the TBEV-positive tick, which contained a TBEV strain unrelated to TBEV-NL, on the *Utrechtse heuvelrug* in 2016.

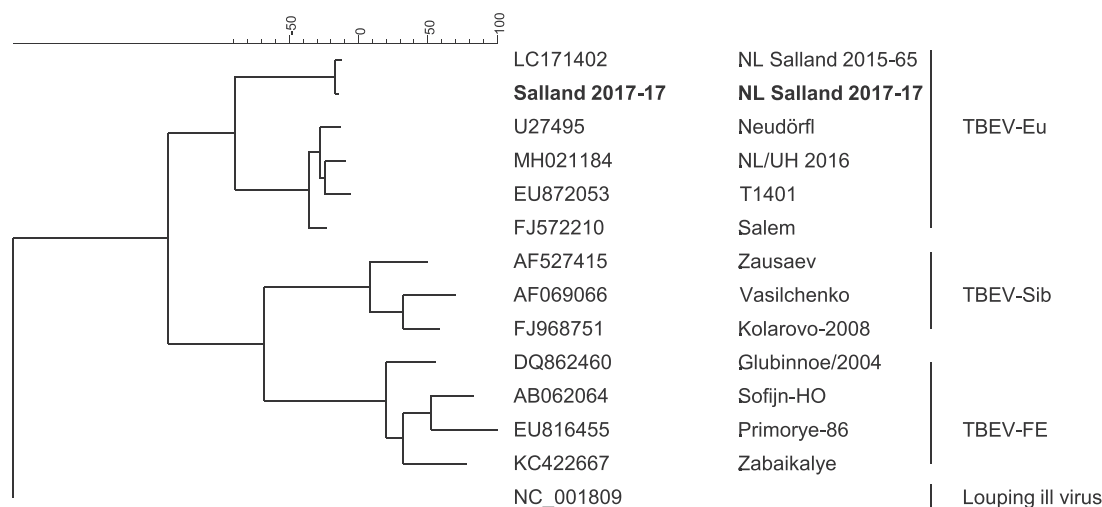


Fig. 2. Phylogenetic tree calculated for the E gene of tick-borne encephalitis virus (nt 900-2439 based on strain Neudörfl, GenBank sequence U27495). Sequence generated in this study is indicated in bold.

have been found (Fig. 1). The geographic clustering of these two TBE patients and TBEV-positive ticks in a country where so far three endemic cases have been reported raises the question whether this area may represent a TBEV hot spot within the *Sallandse heuvelrug* region and a possible risk area for contracting TBE.

TBEV hot spots or ‘micro-foci’ have been described as areas of intense virus circulation within endemic areas or ‘natural foci’ and may be the result of overlap in time and space of the habitats of various host reservoirs, being small mammals, within regions where a combination of botanical, zoological, climatological and geographical factors sustains virus circulation (Süss et al., 1999). Within these micro-foci ticks are more frequently infected with TBEV than ticks in the rest of the natural focus, but the exact prevalence in such micro-foci is often not known (Süss et al., 1999).

Of the 63 ticks collected within the vicinity of patient A’s home in 2017, one adult tick tested positive (1.59% (CI 0.04%–8.53%)). This is surprisingly, given that in the initial survey of seven different areas on the *Sallandse heuvelrug* only 2 (1 nymphal pool (n = 5) and 1 adult pool (n = 2)) of 1460 *I. ricinus* ticks (1160 nymphs and 300 adults) collected in 2015 were found positive for TBEV (0.14% (CI 0.05%–0.49%)). In the area where the two TBEV-positive ticks were found 518 ticks in total had been collected and investigated (0.39% (CI 0.05%–1.39%)) (Jahfari et al., 2017). The higher frequency of TBEV-positive ticks in this catch may be coincidence, or otherwise suggestive of a higher TBEV prevalence in that particular area, which would support the presence of a possible hot spot in the *Sallandse heuvelrug* region. The strong identity (99.5%) of the TBEV strain from 2017 with the previous identified TBEV-NL strain from 2015 supports the concept of continued circulation of TBEV-NL in the Netherlands.

Defining a TBE risk area in the emerging phase of the disease is difficult. Classic methods to characterize a risk area include assessment of the prevalence of TBEV-infected ticks, TBEV-infected hosts, autochthonous clinical cases, and anti-TBEV antibodies in the population. In addition, other estimates may be used like the prevalence of anti-TBEV antibodies in non-reservoir host animals (for instance deer and livestock; Süss et al., 1999). However, an up-to-date assessment of the risk of contracting an infection utilizing all the above-described prevalence data turns out impractical in general. A more pragmatic definition dating from 1998 posed in Germany, where TBEV is endemic for a long time, states risk areas as administrative districts with 5 or more cases of TBE per 5 years. High risk areas are districts with 25 or more cases per 5 years (Kaiser, 1999). However, using this definition with an average of one case a year so far, it could take up to five years before this area may be defined as a risk area. Investigation of other criteria like further

assessment of the TBEV prevalence in ticks in the area of the two cases seems to be warranted to better assess the risks in the emerging phase of this zoonotic disease. Since the identification of the first TBEV-positive ticks and autochthonous TBE cases in the Netherlands risk assessment by the National Institute for Public Health and the Environment (RIVM) is ongoing.

TBE is a preventable disease and efficacious vaccines against TBEV are available. The effectiveness of current European vaccines against the TBEV-NL remains to be proven, but it seems likely that these will be cross-protective. It was shown in a human study that a TBE vaccine based on the TBEV-Eu Neudörfl strain induces equal amounts of neutralizing antibodies against the TBEV-Sib and TBEV-FE subtypes, which are more distantly related to the TBEV-Eu Neudörfl strain than the TBEV-NL strain is (Orlinger et al., 2011; see also Fig. 2).

Concluding, a third case of autochthonous TBE in the Netherlands was identified. The majority of autochthonous TBE cases in the Netherlands as well as TBEV-positive ticks reported so far are now geographically clustered within a relatively small area where there is shown to be continued circulation of TBEV-NL, questioning the presence of a TBEV hot spot within the *Sallandse Heuvelrug* region. Further risk assessment is needed to guide advising on preventive measures as for instance vaccination to prevent TBEV infection.

Informed consent

Informed consent was obtained from patient A and patient B.

Conflict of interest

The authors have nothing to disclose.

Funding

This research did not receive any specific grant from funding agencies in the public, commercial, or not-for-profit sectors.

Authors’ contributions

M. Dekker and G.D. Laverman were responsible for the clinical diagnosis and management. F. Geeraedts and M. Dekker wrote the initial draft of this article. All authors were involved in further adjusting the paper. J. Reimerink and F. Geeraedts were responsible for microbiological laboratory testing. G.D. Laverman, J. Reimerink, A. de Vries, and F. Geeraedts were involved in tick collection and testing. A. de

Vries performed the sequence analysis of the TBEV genomic RNA.

Acknowledgements

We thank Prof. Dr. H. Holzmann from the Medical University Vienna, Austria, for performing the virus neutralization assay.

References

- Dai, X., Shang, G., Lu, S., Yang, J., Xu, J., 2018. A new subtype of eastern tick-borne encephalitis virus discovered in Qinghai-Tibet Plateau, China. *Emerg. Microbes Infect.* 7, 74.
- de Graaf, J.A., Reimerink, J.H., Voorn, G.P., Bij de Vaate, E.A., de Vries, A., Rockx, B., Schuitemaker, A., Hira, V., 2016. First human case of tick-borne encephalitis virus infection acquired in the Netherlands, July 2016. *Euro Surveill.* 21 <https://doi.org/10.2807/1560-7917.ES.2016.21.33.30318>. pii = 30318.
- Donoso Mantke, O., Aberle, S.W., Avsic-Zupanc, T., Labuda, M., Niedrig, M., 2007. Quality control assessment for the PCR diagnosis of tick-borne encephalitis virus infections. *J. Clin. Virol.* 38, 73–77.
- Holzmann, H., 2003. Diagnosis of tick-borne encephalitis. *Vaccine* 21 (Suppl. 1), 36–40.
- Jahfari, S., de Vries, A., Rijks, J.M., Van Gucht, S., Vennema, H., Sprong, H., Rockx, B., 2017. Tick-borne encephalitis virus in ticks and roe deer, the Netherlands. *Emerg. Infect. Dis.* 23, 1028–1030.
- Kaiser, R., 1999. The clinical and epidemiological profile of tick-borne encephalitis in southern Germany 1994-98: a prospective study of 656 patients. *Brain* 122, 2067–2078.
- Kaiser, R., 2012. Tick-borne encephalitis: clinical findings and prognosis in adults. *Wien. Med. Wochenschr.* 162, 239–243.
- Kovalev, S.Y., Mukhacheva, T.A., 2017. Reconsidering the classification of tick-borne encephalitis virus within the Siberian subtype gives new insights into its evolutionary history. *Infect. Genet. Evol.* 55, 159–165.
- Kupča, A.M., Essbauer, S., Zoeller, G., de Mendonça, P.G., Brey, R., Rinder, M., Pfister, K., Spiegel, M., Doerrbecker, B., Pfeffer, M., Dobler, G., 2010. Isolation and molecular characterization of a tick-borne encephalitis virus strain from a new tick-borne encephalitis focus with severe cases in Bavaria, Germany. *Ticks Tick Borne Dis.* 1, 44–51.
- Lindquist, L., Vapalahti, O., 2008. Tick-borne encephalitis. *Lancet* 371, 1861–1871.
- National Institute for Public Health and the Environment (RIVM), 2016. Tekenencefalitisvirus aangetroffen in Nederlandse teken. [Tick-borne encephalitis virus found in Dutch ticks]. [Accessed 14 March 2016]. Dutch. Available from: http://www.rivm.nl/Documenten_en_publicaties/Algemeen_Actueel/Nieuwsberichten/2016/Teken_encefalitisvirus_in_Nederland_aangetroffen.
- Orlinger, K.K., Hofmeister, Y., Fritz, R., Holzer, G.W., Falkner, F.G., Unger, B., Loew-Baselli, A., Poellabauer, E.M., Ehrlich, H.J., Barrett, P.N., Kreil, T.R., 2011. A tick-borne encephalitis virus vaccine based on the European prototype strain induces broadly reactive cross-neutralizing antibodies in humans. *J. Infect. Dis.* 203, 1556–1564.
- Schwaiger, M., Cassinotti, P., 2003. Development of a quantitative real-time RT-PCR assay with internal control for the laboratory detection of tick borne encephalitis virus (TBEV) RNA. *J. Clin. Virol.* 27, 136–145.
- Süss, J., Schrader, C., Abel, U., Voigt, W.P., Schosser, R., 1999. Annual and seasonal variation of tick-borne encephalitis virus (TBEV) prevalence in ticks in selected hot spot areas in Germany using a nRT-PCR: results from 1997 and 1998. *Zentralbl. Bakteriologie* 289, 564–578.
- Veje, M., Studahl, M., Norberg, P., Roth, A., Möbius, U., Brink, M., Bergström, T., 2014. Detection of tick-borne encephalitis virus RNA in urine. *J. Clin. Microbiol.* 52, 4111–4112.
- Weststrate, A.C., Knapen, D., Laverman, G.D., Schot, B., Prick, J.J., Spit, S.A., Reimerink, J., Rockx, B., Geeraedts, F., 2017. Increasing evidence of tick-borne encephalitis (TBE) virus transmission, the Netherlands, June 2016. *Euro Surveill.* 22 <https://doi.org/10.2807/1560-7917.ES.2017.22.11.30482>. pii = 30482.